JOURNAL OF CLINICAL MEDICINE OF KAZAKHSTAN (E-ISSN 2313-1519)
Original Article DOI: https://doi.org/10.23950/jcmk/11959

Clinical outcome of percutaneous common extensor tenotomy for recalcitrant lateral humeral epicondylitis

Sandeep Dathik[1], Rajesh Kumar Chopra[2], Ashish Jaiman[2]

[1]*Orthopaedics Department, Jai Hind Healthcare, Charkhi Dadri, Haryana, India*
[2]*Orthopaedics Department, Central Institute of Orthopaedics, Vardhman Mahavir Medical College & Safdarjung Hospital, New Delhi, India*

Received: 2021-12-30.
Accepted: 2022-04-02

J Clin Med Kaz 2022; 19(2):57-61

Corresponding author:
Sandeep Dathik.
E-mail: drsandeepdathik@gmail.com;

Abstract

Introduction: Tennis elbow is a commonly encountered problem in orthopaedic clinical practice. The patients are usually in their financially productive years and many a times, this is a work related disorder that becomes severe enough leading for lost work days. Conservative treatment is almost always the first choice; but once it fails, there is no clear consensus for the management of recalcitrant cases. We undertook this study to evaluate the clinical outcomes of percutaneous tenotomy in cases of resistant lateral epicondylitis.

Materials and methods: This was a prospective study done over a period of 5 years. A total of 108 patients with recalcitrant tennis elbow were recruited and underwent percutaneous tenotomy. They were followed up for an average period of 14 months. The outcomes measured were: tenderness, DASH score, Roles & Maudsley scale, Visual analogue scale (VAS), and Grip strength. Statistical analysis was done using Paired t-test.

Results: 95% patients were pain free after an average of 12 weeks. The 6 months postoperative improvement in VAS score was 6.84 and change in mean DASH score was 23.04. The average increase in mean grip strength was 13.30 kg. These results were statistically significant.

Conclusion: Percutaneous tenotomy can be considered as a useful treatment option for resistant cases of tennis elbow.

Key words: lateral epicondylitis, office procedure, percutaneous tenotomy, tennis elbow

Introduction

Lateral humeral epicondylitis (tennis elbow) is a frequently occurring musculoskeletal condition presenting to the orthopaedic clinic. The condition is usually a 'repetitive strain injury' and is seen in patients performing work related repeated and forceful supination and pronation of the forearm with the elbow in extension [1, 2]. The annual incidence is 1-3% of the U.S. population. Runge is credited to first describe this condition in 1873 [3]. Contrary to its name, it commonly affects non tennis players and workers.

Clinically the disease manifest itself as pain over the radial aspect of elbow exacerbated by resisted extension of the wrist and by making a fist. Symptoms are usually mild, but occasionally they flare up so severely as to prevent lifting or holding a book or even a cup. The significant pain and disability can be enough to cause a working man to leave his job [2, 4].

Clinically, tenderness is localized to outer epicondyle and to a centimeter distal to lateral epicondyle onto the common extensor muscles. Pain is aggravated by wrist extension against resistance in the pronated position, particularly with elbow in extension. Elbow and wrist range of motion are typically not affected [5]. Differential diagnosis typically includes other causes of pain on radial side of elbow e.g. radial tunnel syndrome, lateral collateral ligament injury, elbow arthritis, and osteochondritis of the capitellum. They must be excluded before reaching a diagnosis of lateral epicondylitis.

With time, pathoanatomy of lateral epicondylitis has become conclusive and has guided treatment methodologies. Histopathology of the affected Extensor

Carpi Radialis Brevis (ECRB) attachment has demonstrated non-inflammatory angiofibroblastic tendinosis with neovascularization, a disordered collagen scaffold, mucoid degeneration, and micro tears [6, 7].

Currently available non-operative treatment methods include rest, nonsteroidal anti-inflammatory drugs, ultrasonic therapy, steroid injections, counterforce brace, and stretching and deep friction massage. Off late, extracorporeal shock waves, laser light and non-coherent light therapy have also come into picture. Similarly, the recent fad of injecting platelet rich plasma has not left Lateral Epicondylitis untouched [8, 9].

Failure of the above non operative modalities, taken for at least 6 months is an indication for surgical management of the disease. By an estimate, 8% fail to respond to non-operative means, and this is the subgroup that might require surgery [10]. Several surgical procedures like open surgical debridement, common extensor origin release, endoscopic techniques and percutaneous tenotomy have been pronounced in texts [3, 11]. It is unclear which procedure is best.

A direct approach to the pathology i.e. open ECRB release has some downsides like protracted postoperative recovery time, a risk of posterolateral instability of the elbow due to lateral ligament injury, and the formation of cutaneous neuroma.

Another approach i.e. Endoscopic ECRB release has a long learning curve and has issues with re-suturing of the detached ECRB. Therefore we felt that a minimally invasive approach like percutaneous common extensor tenotomy shall be tried for recalcitrant lateral epicondylitis.

So far, literature is unclear on superiority of one procedure over the other and most studies have proved a success rate of more than 80 percent. We undertook this study to evaluate the clinical results and functional outcome of percutaneous tenotomy of common extensor origin performed in the out-patient setup in cases of recalcitrant lateral humeral epicondylitis.

Material and methods

A prospective study was conducted at our hospital in 5 years (from 2011 to 2016) on 108 patients. They go through percutaneous release of the common extensor origin. Average follow up period was 14 months.

Patients presenting to the outpatient department were enlisted for the study; provided they meet inclusion and exclusion criteria. An informed written consent was taken from all of the recruited patients. Proper approval was taken from the institutional ethics committee of the hospital.

Inclusion Criteria:

Patients of either sex with a proven clinical diagnosis of lateral epicondylitis of the elbow along with-

1. Failure of at least six months of non-operative treatment including minimum 4 of the following- nonsteroidal anti-inflammatory drugs, steroid injections, physical therapy, stretching exercises and tennis elbow brace, and unacceptable quality of life.

2. Pain induced by two or more of these diagnostic tests

a. Palpation of the lateral epicondyle

b. Resisted wrist extension (Thomsen test)

c. Chair test: With the shoulder flexed to 60° and the elbow extended, the patient attempts to lift a chair weighing 3.5 kg.

Exclusion Criteria (any one of the following):

Age less than 18 years, complain of generalized polyarthralgia, presence of local infection, history malignancy, and radiological evidence of elbow arthritis, ipsilateral shoulder disorder and radial tunnel syndrome.

Operative Technique

The procedure was performed under local anesthesia and as an OPD procedure under all aseptic precautions [3, 12]. Patient was kept supine with the elbow was kept flexed at 90 degrees. This advances the radial nerve volarly from the tenotomy incision. No tourniquet was used in the procedure. Steps that were followed were-

1) Palpated the posterior edge of the lateral epicondyle, and made a fingernail impression at a point 1 cm anterior to this edge and at the midpoint of the width of the epicondyle

2) Inserted the local anesthetic needle at this exact point and infiltrated the entire region

3) Inserted a number 11 blade at the needle entrance side and cut through the entire width of the common extensor origin from proximal to distal in a direction parallel to the axis of humerus. Skin pliability allows the superficial incision to be one fourth inch long while a three-fourth inch tenotomy is accomplished (Figure 1) (adapted from http://www.phyzio.biz/tennisElbow.php).

Figure 1 - Incision site for percutaneous common extensor tenotomy

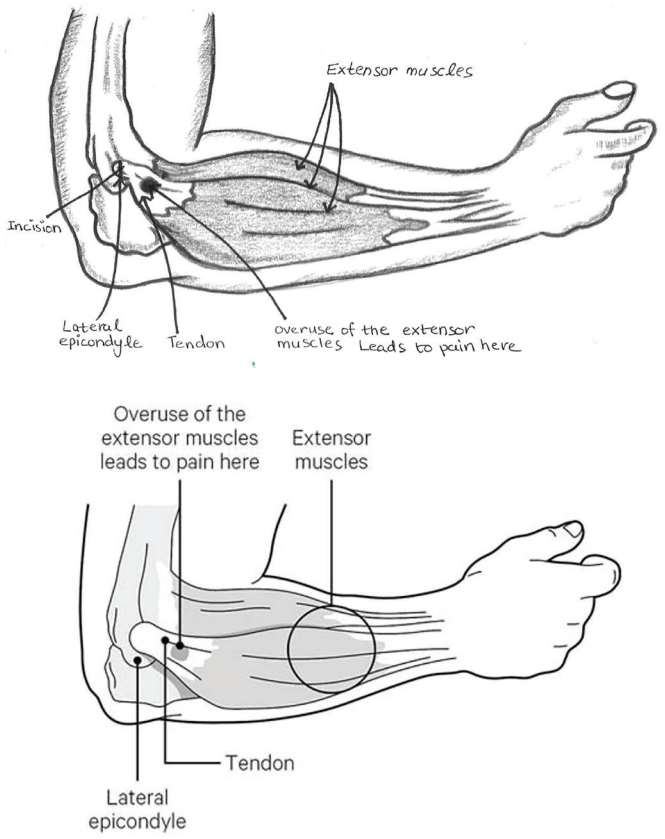

4) While digital pressure was maintained to control bleeding, the wrist was flexed to complete the procedure. No suturing was required.

5) A small sterile gauge was then placed with a pressure dressing over the wound. The dressing was removed on the seventh day.

Assessment

Functional assessment was done at follow-up of 4-weekly intervals for a minimum of 6 months and then every 3 months for the next 1½ years. We assessed at every follow up-

1. Tenderness at the lateral epicondyle.

2. Disabilities of the Arm, Shoulder and Hand (DASH)

Table 1 On Visual Analogue Scale mean difference was 6.84 with p value of .0001 at 6 months follow up.

Time	Range	Minimum	Maximum	Mean	Std. Deviation
0 weeks	2	7	9	8.08	.60
4 weeks	4	3	7	4.69	1.03
8 weeks	3	2	5	3.42	.73
12 weeks	3	1	4	2.31	.74
16 weeks	3	1	4	1.58	.64
20 weeks	3	1	4	1.31	.62
24 weeks	4	0	4	1.14	.68

Table 2 Mean DASH score dramatically decreased from 71.35 to 48.31

Time	Range	Minimum	Maximum	Mean	Std. deviation
0 weeks	30	58	88	71.35	6.97
4 weeks	24	51	75	62.75	6.03
8 weeks	30	46	76	57.81	5.58
12 weeks	32	42	74	54.86	5.57
16 weeks	29	42	71	51.36	4.77
20 weeks	32	40	72	49.42	5.16
24 weeks	32	40	72	48.31	5.11

score: The DASH questionnaire was used to get data regarding capacity to recommence daily activities, occupational activities, and sports.

3. Roles & Maudsley scale: for clinical assessment

4. The Visual Analogue Scale (VAS): was used for evaluation of pain.

5. Grip strength of both hands: measurement of grip strength of both hands was done using a hand dynamometer. Quantifications were made with the elbow fully extended and then flexed to 90 degrees. The mean of the two measurements was recorded as the grip strength.

6. Any complication: if found, was reviewed and managed.

Statistical analysis

Paired student t-test was applied for statistical analysis. SPSS software was used for paired t test.

Results

The mean age of the patients we studied was 44.5 years. Dominant hand was involved in 78% of the patients. The post-operative improvement in mean VAS score (Table 1) was 6.84 (p= .0001) at 6 months and change in mean DASH score (Table 2) was 23.04 (p= .0001) (Table 3). The average increase in mean grip strength was 13.30 kg (Table 4) with a p value of .0001 (Table 5). The overall results according to Roles and Maudsley rating scale (Table 6) were excellent in 94 elbows (87.03%), good in 9 elbows (8.33%), fair in 3 elbows (2.77%) and poor in 2 elbows (1.85%) because of the recurrence. In 95% of the patients lateral epicondylar pain was relieved at the mean duration of 12 weeks after the surgery. All patients had a full range of elbow and wrist movement at follow up examination. One patient developed synovial fistula. Two patients had superficial infection which resolved after a short course of oral antibiotics. Recurrence of pain occurred in two patients (Table 7). All the patients were very satisfied with minimal post-operative scar (Figure 2, 3, 4, 5).

Table 3 DASH Score showed mean difference of 23.04 with p value of .0001

	Mean	Std. Deviation
Pre procedure	71.35	6.97
Post procedure	48.31	5.11

Table 4 Grip strength measurements in Kg- average increase in mean grip strength was 13.30 kg

Time	Involved side	Control side
0 weeks	22.81±8.68	41.44+10.90
4 weeks	24.83±8.63	41.47±10.93
8 weeks	26.97±9.2	41.42±10.9
12 weeks	29.81±9.6	41.47±11.02
16 weeks	33.53±9.7	41.17±10.7
20 weeks	35.28±9.44	41.64±10.74
24 weeks	36.11±10.01	41.47±10.94

Table 5 Grip Strength p value

Side	
p value*	
Involved side	.0001
Control side	.911

*Paired t test

Table 6 Roles and Maudsley Scale, 87% patients had excellent results at 6 months

		Number of patients	Percentage
Excellent	No pain Full movement Full activity	94	87.03%
Good	Occasional discomfort Full movement Full activity	9	8.33%
Fair	Some discomfort after prolonged activity	3	2.77%
Poor	Pain limiting activities	2	1.85%

Table 7 Complications

Complication	Number of patients	Percentage
Superficial Infection	2	1.85%
Synovial Fistula	1	0.92%
Recurrence	2	1.85%
No Complication	103	95.37%

Figure 2 - Eliciting tenderness at lateral epicondyle

Figure 4 - Completion of the tenotomy

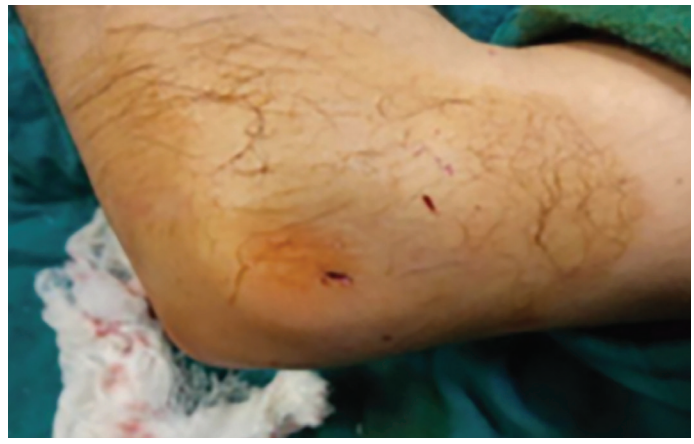

Figure 3 - Release of common extensor origin

Figure 5 - Post-procedure scar of tenotomy at 8 weeks

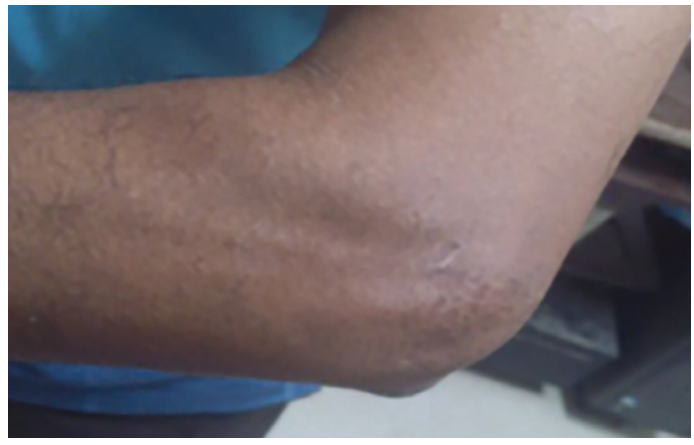

Discussion

The notion that lateral humeral epicondylitis is an auto-limiting condition and does not need any intermediation is not fair for those patients in whom pain and limitation of activities have been upsetting their daily routine for nearly 1-2 years. Greenbaum et al. in their anatomical studies came to the conclusion that "pain of lateral epicondylitis appears to arise more from the 'common extensor' origin", the pathology cannot be isolated to a single structure [13]. Any surgical treatment for recalcitrant lateral epicondylitis should therefore focus on the common extensor origin.

The open debridement approach is the most direct of the available methods; but, there has been a recent increase in reports on per-cutaneous and endoscopic approaches due to a protracted rehabilitation course of open surgery. Insufficient data is available in literature to favor one procedure over the other.

We found very few published reports in the literature concretizing the results of percutaneous release of common extensor origin [14-16]. Keeping these background facts in mind, 108 patients with recalcitrant lateral humeral epicondylitis were treated with percutaneous release of common extensor origin.

The mean age of our patients was 44.5 years. The range was 30-70 years. 36.11% of the patients (n=39) were between 31-40 years and 50% (n=54) were in the age group 41-50 years. This shows that it commonly afflicts middle aged and productive working population [17]. In our study, the mean pre-operative VAS score was 8.08 (range 7-9) and post-operative (6 months) the mean VAS score was 1.14 (range 0-4). Hence, the VAS score changed from 8.08 to 1.14 in pre-operative and postoperative values respectively (Table 1). The results were similar to those of shown by Rayan et al. for extensor fasciotomy of common extensor origin in recalcitrant lateral epicondylitis [18].

The mean pre-operative DASH score (Table 2, 3) in our study was 71.35 (range 58-88) and post-operative (6 months) DASH score was 48.31 (range 40-72). The change in post-operative DASH score was 23.04 (p= .0001).

Average time for pain to disappear was 12 weeks with a range from 10-16 weeks in our study. Almost all patients were free from tenderness at 24 weeks after the procedure was performed. Whereas pain on resisted wrist extension and activity related pain disappeared in 95% (n==103) of patients after 24 weeks of procedure and only 5% had mild to moderate pain.

The grip strength (Table 4, 5) on the affected side and the normal side were measured before and after the release for each patient, and strength on the two sides were compared. Pre-operative mean grip strength on involved side was 22.81+8.68 kg and on control side pre-op mean grip strength was 41.44+10.9 kg. Post-operative mean grip strength on involved side was 36.11+10.01 kg and on control side mean grip strength was 41.47+10.94 kg. The post-operative increase in grip strength was 13.30 kg on involved side (p= .0001) and 0.03 kg on control side (p= .911). This result was significant on involved side.

According to Roles and Maudsley rating system, excellent results were obtained in 94 elbows (87.03%), good in 9 elbows (8.33%), fair in 3 (2.77%) and poor in 2 elbows (2.70%). Yerger [3] et al. has reported 93.5% excellent and good results. Baumgard et al. [14] reported 35 cases of percutaneous release of tennis elbow in which excellent result were achieved in 32 cases (91.4%) while in 3 cases results were unsatisfactory. Powell and Burke followed up 20 patients and showed 85% excellent results

[19]. Nirschl and Pettrone [2] achieved an excellent outcome in 66 of 88 and Verhaar [20] got 46 out of 57 excellent outcomes of tennis elbows using an open technique.

Post-operatively, the complications (Table 7) encountered in our study were synovial fistula in 1 patient and superficial infection in 2 patients. This could be a result of tenotomy being taken too distally, which resolved after 3 weeks of regular dressing and course of antibiotic therapy [21]. There were two cases of recurrence after three months of tenotomy, it might have been due to imperfect release of the common extensor origin. The revision percutaneous tenotomy was performed on the same patients with achievement of a pain free elbow after 8 weeks of procedure. All these three patients achieved excellent results without any loss of elbow and wrist movement.

Conclusion

Resistant lateral epicondylitis remains a difficult therapeutic problem. Various surgical procedures have been described in the literature for recalcitrant lateral epicondylitis. Of all these, percutaneous tenotomy is a modest, benign, minimally invasive, effective and straightforwardly reproducible method of treatment. Furthermore, this procedure can be done as an OPD procedure under local anesthesia. In addition, percutaneous extensor tenotomy very well tackle with the shortcomings of open ECRB & arthroscopic ECRB release i.e. protracted rehabilitation .We recommend that Percutaneous common extensor tenotomy is a beneficial management option for recalcitrant cases of Lateral humeral epicondylitis.

Disclosures: There is no conflict of interest for all authors.

Acknowledgements: None.

Funding: None.

References

1. Boyer MI, Hastings H 2nd. Lateral tennis elbow: "Is there any science out there?". J Shoulder Elbow Surg. 1999;8(5):481-91. https://doi.org/10.1016/s1058-2746(99)90081-2
2. Nirschl RP, Pettrone FA. Tennis elbow. The surgical treatment of lateral epicondylitis. J Bone Joint Surg Am. 1979;61(6A):832-9. https://doi.org/10.2106/00004623-197961060-00005
3. Yerger B, Turner T. Percutaneous extensor tenotomy for chronic tennis elbow: an office procedure. Orthopedics. 1985;8(10):1261-1263. https://doi.org/10.3928/0147-7447-19851001-11
4. Caldwell GL Jr, Safran MR. Elbow problems in the athlete. Orthop Clin North Am. 1995;26(3):465-85. https://doi.org/10.1016/S0030-5898(20)32011-3
5. Calvert PT, Allum RL, Macpherson IS, Bentley G. Simple lateral release in treatment of tennis elbow. J R Soc Med. 1985;78(11) 912-915. https://doi.org/10.1177/014107688507801106
6. Calfee RP, Patel A, DaSilva MF, Akelman E. Management of lateral epicondylitis: current concepts. J Am Acad Orthop Surg. 2008;16(1):19-29. https://doi.org/10.5435/00124635-200801000-00004
7. Grundberg AB, Dobson JF. Percutaneous release of the common extensor origin for tennis elbow. Clin Orthop Relat Res. 2000;(376):137-40. https://doi.org/10.1097/00003086-200007000-00019
8. Cho BK, Kim YM, Kim DS, Choi ES, Shon HC, Park KJ, Lee EM. Mini-open muscle resection procedure under local anesthesia for lateral and medial epicondylitis. Clin Orthop Surg. 2009;1(3):123-7. https://doi.org/10.4055/cios.2009.1.3.123
9. Hastie G, Soufi M, Wilson J, Roy B. Platelet rich plasma injections for lateral epicondylitis of the elbow reduce the need for surgical intervention. J Orthop. 2018;15(1):239-241. https://doi.org/10.1016/j.jor.2018.01.046
10. Posch JN, Goldberg VM, Larrey R. Extensor fasciotomy for tennis elbow: a long-term follow-up study. Clin Orthop Relat Res. 1978;(135):179-82. https://doi.org/10.1097/00003086-197809000-00037
11. Cohen M. Arthroscopic Treatment of Lateral Epicondylitis. In: Wolf J. (eds) Tennis Elbow. Springer, Boston, MA. 2015. https://doi.org/10.1007/978-1-4899-7534-8_12
12. Wang D, Degen RM, Camp CL, McGraw MH, Altchek DW, Dines JS. Trends in Surgical Practices for Lateral Epicondylitis Among Newly Trained Orthopaedic Surgeons. Orthop J Sports Med. 2017;5(10):2325967117730570. https://doi.org/10.1177/2325967117730570
13. Greenbaum B, Itamura J, Vangsness CT, Tibone J, Atkinson R. Extensor carpi radialis brevis. An anatomical analysis of its origin. J Bone Joint Surg Br. 1999;81(5):926-9. https://doi.org/10.1302/0301-620x.81b5.9566
14. Baumgard SH, Schwartz DR. Percutaneous release of the epicondylar muscles for humeral epicondylitis. Am J Sports Med. 1982;10(4):233-6. https://doi.org/10.1177/036354658201000408
15. Tosti R, Jennings J, Sewards JM. Lateral epicondylitis of the elbow. Am J Med. 2013;126(4):357.e1-6. https://doi.org/10.1016/j.amjmed.2012.09.018
16. Dunkow PD, Jatti M, Muddu BN. A comparison of open and percutaneous techniques in the surgical treatment of tennis elbow. J Bone Joint Surg Br. 2004;86(5):701-704. https://doi.org/10.1302/0301-620x.86b5.14469
17. Garden R. S. Tennis elbow. The Journal of Bone and Joint Surgery. British volume. 1961; 43-B(1):100-106. https://doi.org/10.1302/0301-620X.43B1.100
18. Rayan, F., Rao, V.S., Purushothamdas, S. et al. Common extensor origin release in recalcitrant lateral epicondylitis - role justified? J Orthop Surg Res. 2010; 5(31). https://doi.org/10.1186/1749-799X-5-31
19. Stephen G. Powell, April L. Burke, Surgical and therapeutic management of tennis elbow: An update. Journal of Hand Therapy. 1991; 4(2):64-68. https://doi.org/10.1016/S0894-1130(12)80105-0.
20. Verhaar J, Walenkamp G, Kester A, van Mameren H, van der Linden T. Lateral extensor release for tennis elbow. A prospective long-term follow-up study. J Bone Joint Surg Am. 1993;75(7):1034-43. https://doi.org/10.2106/00004623-199307000-00010
21. Coonrad RW, Hooper WR. Tennis elbow: its course, natural history, conservative and surgical management. J Bone Joint Surg Am. 1973;55(6):1177-82. https://doi.org/10.2106/00004623-197355060-00004